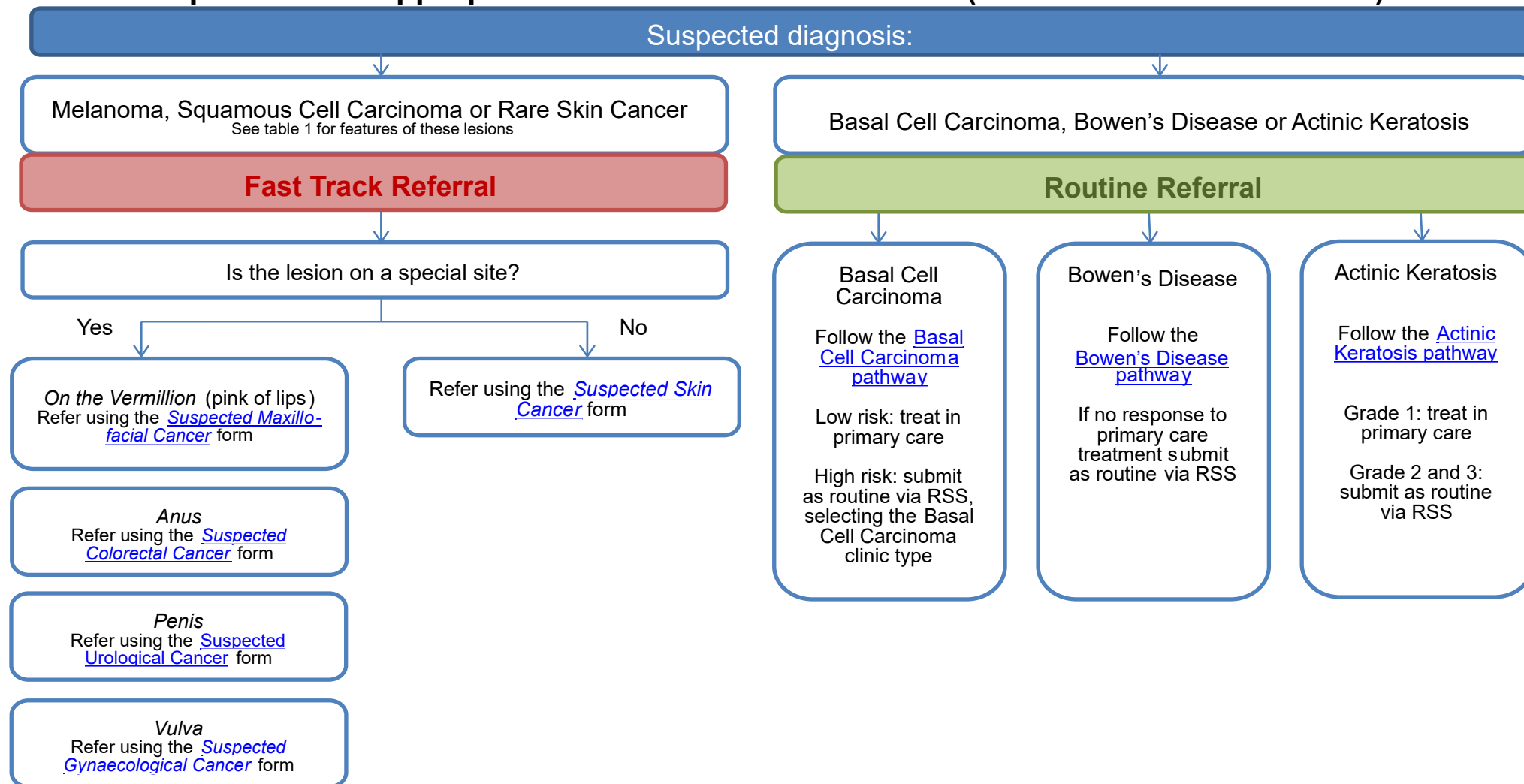




# Suspected Skin Cancer Guidance

Which skin patients are appropriate for a 'Fast-Track' referral? (To be seen within 2 weeks)



Version: 01	Date published: August 2024	Date of review: March 2018
Responsible GP: Dr Joan Meakins		Responsible Consultant: Dr Andy Muinonen-Martin

**Table 1 – Features of Melanomas and Squamous Cell Carcinomas**

<p>Melanoma</p>	<p>Score of 3+ from this 7-point weighted checklist</p> <p><b>Major features of lesion (scoring 2 points each)</b></p> <ul style="list-style-type: none"> <li>• Change in size</li> <li>• Irregular shape</li> <li>• Irregular colour</li> </ul> <p><b>Minor features of lesion (scoring 1 point each)</b></p> <ul style="list-style-type: none"> <li>• Largest diameter 7mm or more <ul style="list-style-type: none"> <li>• Inflammation</li> <li>• Oozing</li> </ul> </li> <li>• Change in sensation</li> </ul>	<p><b>Remember:</b> Melanomas may look like a pyogenic granuloma</p>  <p>Photograph taken from <a href="http://www.pcds.org.uk/clinical-guidance/pyogenic-granuloma#">http://www.pcds.org.uk/clinical-guidance/pyogenic-granuloma#</a></p>
<p>Squamous Cell Carcinoma SCC</p>	<p><b>Possible Features</b></p> <ul style="list-style-type: none"> <li>• Growing in size</li> <li>• Non-healing ulcer</li> <li>• Commonly on face, scalp, back of hand</li> <li>• Induration on palpation</li> <li>• Hard/keratotic surface</li> <li>• Easy bleeding/friable nodule</li> <li>• Occurring in immunosuppressed patient</li> </ul>	<p><b>Remember:</b> SCCs and melanomas may be amelanotic/friable</p>  <p>Photograph taken from <a href="http://www.pcds.org.uk/clinical-guidance/melanoma-an-overview1#!prettyPhoto">http://www.pcds.org.uk/clinical-guidance/melanoma-an-overview1#!prettyPhoto</a></p>

Version: 01	Date published: August 2024	Date of review: August 2027
Responsible GP: Dr Joan Meakins	Responsible Consultant: Dr Andy Muinonen-Martin	